








Case Report

Rare Cesarean Section Scar Ectopic Pregnancy Successfully Treated by Methotrexate: A Case Report

Wassan Nori^{1*} , Ali Muhammad Murad¹ , Nibras Hatim Khamees² , Alexandru Cosmin Pantazi³ 
Mustafa Ali Kassim Kassim³ 

¹Department of Obstetrics and Gynecology, College of Medicine, Mustansiriyah University, Baghdad, Iraq;

²Department of Human Anatomy, College of Medicine, Mustansiriyah University, Baghdad, Iraq; ³Department of Pediatrics, Faculty of Medicine, "Ovidius" University, 900470 Constanta, Romania

Received: 27 August 2023; Revised: 27 September 2023; Accepted: 2 October 2023

Abstract

An ectopic pregnancy embedded in a C-section scar is considered an uncommon and complex sub-type of ectopic pregnancy. This particular condition requires an increased level of clinical suspicion, the use of specific diagnostic tools, and the implementation of customized care measures. Here we present a case of a 37-year-old lady with a history of 3 C-sections presented to the ER department with an acute attack of pain and vaginal bleeding for 1 hour before admission on day 19 of a regular cycle. She gave a six-month history of intermenstrual bleeding and chronic pelvic pain. Her previous bacteriological and pap smears were normal. An earlier pelvic scan showed an Rt ovarian case, a thickened endometrium, and a small mural fibroid. Upon admission, B-HCG was positive; transvaginal ultrasound was negative. B-HCG titers confirmed the EP, and an MRI scan confirmed CsEP. She was managed medically with methotrexate and showed a good response. Clinicians must exercise diligence in evaluating patients with a prior history of cesarean sections and who are currently experiencing symptoms of pelvic pain and irregular uterine bleeding. The timely identification and intervention of this complex ailment are crucial to minimize the potential hazards involved and optimize the patient's overall prognosis.

Keywords: B-HCG titer, Caesarian delivery, C-section ectopic pregnancy, Methotrexate, Transvaginal ultrasound.

حالة نادرة للحمل في ندبة العملية القيصرية خارج الرحم عولجت بنجاح باستخدام الميثوتريكسات: تقرير حالة

الخلاصة

يعتبر الحمل خارج الرحم المضمن في ندبة الولادة القيصرية نوعاً فرعياً غير شائع ومعقد من الحمل خارج الرحم. تتطلب هذه الحالة الخاصة زيادة مستوى الشك السريري، واستخدام أدوات تشخيصية محددة، وتنفيذ تدابير رعاية متخصصة. نقدم هنا حالة سيدة تبلغ من العمر 37 عاماً لها تاريخ من 3 عمليات قيصرية حضرت إلى قسم الطوارئ مع نوبة حادة من الألم ونزيف مهبلية لمدة ساعة واحدة قبل الدخول في اليوم 19 من دورة منتظمة. أعطت تاريخاً لمدة ستة أشهر من نزيف ما بين الحيض والام الحوض المزمنة. كانت الفحوصات البكتريولوجية وعنق الرحم السابقة طبيعية. أظهر فحص الحوض السابق حالة كيس بسيط على المبيض الايمن، وبطانة الرحم السمكية، وورم ليفي جداري صغير. عند ادخالها الى ردهة الطوارئ كان B-HCG ايجابياً. فحص الموجات فوق الصوتية عبر المهبل كانت سلبية. أكدت مستويات B-HCG وجود حمل خارج الرحم وأكد فحص التصوير بالرنين المغناطيسي الحمل في ندبة العملية القيصرية خارج الرحم. تم علاجها باستخدام الميثوتريكسات وأظهرت استجابة جيدة. يجب على الأطباء ممارسة الاجتهاد في تقييم المرضى الذين لديهم تاريخ سابق من العمليات القيصرية والذين يعانون حالياً من أعراض الام الحوض ونزيف الرحم غير المنتظم. يعد تحديد هذا المرض المعقد والتدخل فيه في الوقت المناسب أمراً بالغ الأهمية لتقليل المخاطر المحتملة التي ينطوي عليها الأمر وتحسين التشخيص العام للمريض.

* **Corresponding author:** Wassan Nori, Department of Obstetrics and Gynecology, College of Medicine, Mustansiriyah University, Baghdad, Iraq; Email: dr.wassan76@uomustansiriyah.edu.iq

Article citation: Nori W, Murad AM, Khamees NH, Pantazi AC, Kassim MAK. Rare cesarean section scar ectopic pregnancy successfully treated by methotrexate: A case report. *Al-Rafidain J Med Sci.* 2023;5:242-246. doi: <https://doi.org/10.54133/ajms.v5i.274>

© 2023 The Author(s). Published by Al-Rafidain University College. This is an open access journal issued under the CC BY-NC-SA 4.0 license (<https://creativecommons.org/licenses/by-nc-sa/4.0/>).



INTRODUCTION

Cesarean section scar ectopic pregnancy (CsEP) occurs when the fertilized egg implants inside or in close proximity to the scar tissue resulting from a prior cesarean birth. The absence of typical defensive mechanisms in the uterine lining makes this type of ectopic pregnancy more dangerous, showing higher rates of uterine rupture and substantial hemorrhaging due to the scar's delicate nature [1]. A history of prior cesarean sections increases the likelihood of faulty implantation. Likewise, a previous uterine surgery, including dilatation and curettage, a previous hysterotomy, and recent instrumentation [2]; an abnormal uterus, such as a septated uterus; and assisted reproductive techniques represent another risk factor [3]. There are two recognized variations of CsEP. *Type 1* arises within the myometrium and progresses into the uterine cavity, while *type 2* progresses exophytically outside the cavity to the serosa [4]. The latter has a grave prognosis due to the potential for spontaneous uterine rupture, bleeding, and maternal loss [5]. Some cases may be asymptomatic and accidentally discovered, while others may present with symptoms such as abnormal vaginal bleeding and pelvic discomfort. The rarity of this condition, estimated to be 1 in 2000 pregnancies, and its similarity to other medical conditions such as abortion, ovarian cyst accidents, and molar pregnancy delay the diagnosis [5,6]. Conventional ultrasound plays a major role in many aspects of practice; however, its efficacy in spotting scar tissue can occasionally be limited. Transvaginal color Doppler ultrasonography can be employed to identify blood flow patterns that are suggestive of the presence of a CsEP [5,7,8]. Laboratory tests, like serial assessments of B-human chorionic gonadotropin (B-hCG) titers, are still very important for keeping track of how ectopic pregnancies are progressing. Atypical B-hCG titers may raise suspicion, showing a slower or suboptimal rise titer [9]. Nevertheless, an early and precise diagnosis of CsEP frequently necessitates the integration of ultrasound observations, a comprehensive clinical history, and measures of B-HCG [1]. This reinforces the necessity for increased vigilance among healthcare professionals when assessing individuals with a prior history of cesarean deliveries who exhibit the above symptoms. CsEP management is a multifaceted and intricate process. One option is medicinal management with methotrexate, or the case may be managed expectantly. Alternatively, the surgical option involves more intrusive procedures such as laparoscopy or even hysterectomy [1,2]. The technique selection is contingent upon several considerations, including the patient's general health status, future reproductive desires, and the degree of tissue involvement [10]. Here, we present the case of a woman who was brought to our ER department after a long

history of intermenstrual bleeding complicated with acute, painful bleeding.

Case History

Mrs. R., 37 years old, G3 P3 A0, presented to the ER department with a sudden attack of vaginal bleeding of a moderate amount associated with abdominal pain for an hour. The patient was on day 19 of her menstrual cycle. She reported an earlier attack of abnormal uterine bleeding (mostly intermenstrual bleeding after her 7-day menses finished; not as heavy as the current one) in the last six months, for which she consulted a gynecologist. A history of chronic back pain was also reported, mainly affecting her right side; however, upon admission, the pain was different; she described a colicky pain in her lower abdomen radiating to the groin and lower back, followed by a gush of vaginal bleeding. She described it as if the pain was intense enough to trigger the bleeding, and it then settled once the bleeding began. Her past medical history and drug allergies were negative; she had three C-sections, the last one 12 years ago, and she was operated on for acute appendicitis 7 years ago. She was on combined oral contraceptive pills for four months and stopped taking the pills 2–6 months earlier due to adversity. The patient seeks gynecological advice regarding the intermenstrual bleeding she has suffered for the last six months. The examination was normal, with no enlarged uterus, tenderness, or adnexal mass. She was sent for a high-vaginal swap, which showed no growth. A Pap smear reveals mild cervical dysplasia with no malignant cells. An ultrasound showed that the endometrium was 12 mm thicker than usual during the early follicular phase. There was also a single 20 x 22 mm ovarian cyst in the right ovary and small 7 x 8 mm intramural fibroids in the upper anterior part of the uterus. On admission, the patient was slightly pale and anxious, with a PR of 110 and a BP of 110/70. Abdominal examination showed mild suprapubic tenderness, no rebound tenderness, and normal bowel sounds. A per-vaginal exam showed a normal-sized uterus, mild cervical tendencies, no adnexal mass, and a normal cul-de-sac. A blood sample was sent; her Hb was 11.7, her WBC counts were 9.6, and her blood urea, creatinine, and liver enzymes were all normal. CRP was less than 15, and B-HCG was positive. She was sent for another pregnancy test with a quantitative value; B-HCG Titer was 1800 mIU/ml. An urgent ultrasound was done to confirm the site and exclude a ruptured ectopic pregnancy (EP). Transvaginal ultrasound (TVUS) could not locate the EP; no intrabdominal or intrapelvic collection was seen. The uterus was empty and normal in size, with a right ovarian cyst of 20 x 18 mm (Figure 1 A and B). Vitally, the patient was stable; she was admitted and kept under observation as a case of EP in an unknown location. An MRI was done and revealed the presence of a well-defined cystic lesion in the lower uterine segment at the site of the previous scar of 8.7 x

8 mm not extending into the urinary bladder, suggesting a C-scar ectopic pregnancy (Figure 2), and advised following the cases with B-HCG titer. 48 hours later, the B-HCG titer was done; it was 1843 mIU/mL. After counseling the patients and explaining the condition, the decision was made to manage the case by medical option, i.e., methotrexate. 1 week following the injection of methotrexate B-HCG, it was 944.5; 3 days later, it was 473.2 mIU/ml; 7 days later, it was 25.45 mIU/ml. Finally, 10 days later, it became 2.67 mIU/mL.

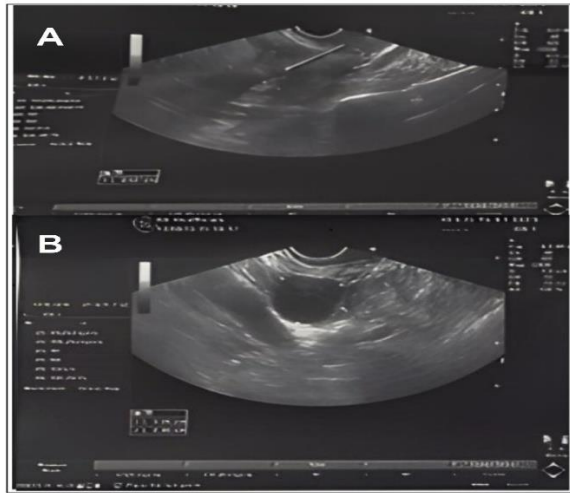


Figure 1 (A and B): The image is TVUS of the patient on admission day, showing a normally sized uterus, an endometrium thickness of 8.7 mm, a small fibroid, and a right ovarian cyst of 20 X 18 mm. There were no signs of intra- nor extrauterine gestational sac; the cul de sac was clear.

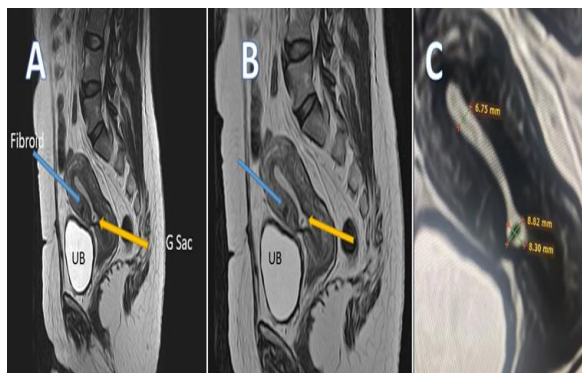


Figure 2: MRI images showing the presence of a well-defined cystic lesion in the lower uterine segment at the site of the previous scar of 8.7 X 8.0 mm (demarcated by an orange arrow) not extending into the urinary bladder, suggesting a C-scar ectopic pregnancy (A and B). There is a small anterior fibroid demarcated by a blue arrow. The endometrial thickness is measured 6.75 mm, and the gestational sac (C).

DISCUSSION

C-section scar Ectopic pregnancy (CsSEP) is a rare entity that is showing rising incidents in the literature

[1,11]. This case was presented after a long history of abnormal uterine bleeding superimposed by sudden-onset pain and bleeding. A thickened endometrium, fibroids, or an ovarian cyst are just a few potential causes of this bleeding [12]. It is not unusual to have asymptomatic cases, which are reported in one-fourth of the literature, so physicians ought to have a high index of susceptibility so such cases are not missed [5]. Indeed, pregnancy should be excluded in any case of bleeding at reproductive age [13]. The positive B-HCG raised the possibility of EP, while TVUS failed to diagnose and locate the ectopic pregnancy. It is not unusual for the 2-dimensional US to miss the diagnosis; if we used the 3-dimensional US, it would probably perform better and diagnose the case. The 3-dimensional US has good discrimination power comparable to the MRI's high soft tissue resolution [14]. MRI imaging showed type I CsSEP, which is seen in 66 percent of patients [11]. The surgical approach is the predominant choice for managing CsSEP, exhibiting a success rate of 97% across a wide range of cases and offering a more favorable complication profile. However, similar to any surgical procedure, there are potential complications associated with anesthesia and surgery [15]. The medical and expectant options for ectopic success rates are comparatively lower, with the medical option exhibiting an overall success rate of 62 percent. Medical interventions can be administered in a systemic manner, locally, or through a combination of both approaches [11,16]. Medical interventions have a higher potential for complications, including hemorrhaging, uterine rupture, and the need for hysterectomies. Furthermore, there is a risk of treatment failure if the B-HCG titer does not decay, necessitating the exploration of alternative therapeutic approaches [17]. This case was vitally stable; her B-HCG titer was below 5000 IU, and she was cooperative. After explaining the condition and the pros and cons of the medical option, the medical option was chosen. The patient's response to therapy was acceptable, and she reported minor side effects of nausea and fatigue. In most cases subjected to medical management, the primary indication for further treatment was a failure to reduce the B-HCG titer. The management of these conditions [5,11] can be achieved through options summarized in Figure 3.

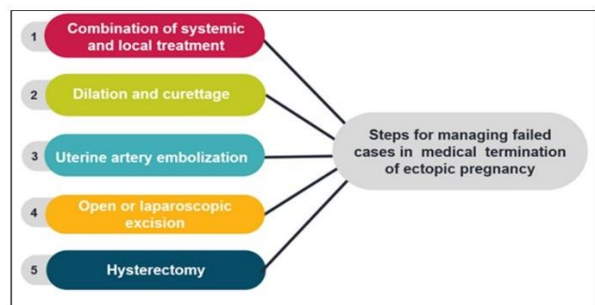


Figure 3: The currently available options to manage failed medical termination of a C-section scar ectopic pregnancy.

The combination of systemic methotrexate and local therapy (injecting KCL guided by laparoscopy) showed a favorable outcome, reaching a 70 percent success rate [18]. In Table 1, we present a comprehensive overview of published studies with respect to modalities of

methotrexate introduction, success rates, complications, and supporting references [19–27]. Uterine artery embolization, a form of interventional radiology, was used alone or combined with medical treatment by direct injection of methotrexate into uterine arteries or used before surgery for one week or so [28].

Table 1: A comprehensive overview of published studies regarding the use of methotrexate, success rates, complications, and supporting references.

Medical intervention	Success rate (%)	Days for B-HCG Decay	Reported Complication	Supporting references
Systemic and local	77	48±10	Hemorrhage 11% Hysterectomy 3.9%	Ko <i>et al.</i> , 2015 [19] Michaels <i>et al.</i> , 2015 [20] Ouyang <i>et al.</i> , 2015 [21]
Local	60	46±6	Hemorrhage 4% Hysterectomy 2.3%	Polat <i>et al.</i> , 2015 [22] Kong <i>et al.</i> , 2015 [23] Seow <i>et al.</i> , 2013 [24]
Systemic	56	42±17	Hemorrhage 6% Hysterectomy 3%	Kutuk <i>et al.</i> , 2014 [25] Wang. <i>et al.</i> , 2013 [26] Li <i>et al.</i> , 2011 [27]

Although the medical option is appealing since it is minimally invasive, methotrexate has a lower success rate in CsEP than in tubal EP. This may be attributed to the fibrous tissue surrounding the gestational sac when embedded in the C-section scar, making it difficult for the drug to be absorbed and work [29]. It is worth mentioning that using multidose methotrexate only increased its side effects without having a beneficial effect on its effectiveness [30]. Several challenges cast a shadow on the field of CsEP. One notable challenge is the absence of standardized diagnostic criteria, which results in diverse diagnoses and treatments being employed across different healthcare settings [31]. Currently, there is a lack of well-established optimal management approaches, highlighting the need for evidence-based guidelines that consider both patient preferences and the extent of scar tissue [11,32]. The long-term effects of CsEP on subsequent fertility and pregnancies are little understood [33]. The same thing applies to employing prevention strategies, whether through clinical practices or patient education, which is constrained [34].

Conclusion

CsEP should be expected in any case of abnormal vaginal bleeding with a history of previous C-sections and recent instrumentation. Confirming the case can impose diagnostic challenges, especially when clinical symptoms are few due to the lack of specific signs on examination and the failure of the ultrasound. Exclusion of pregnancy should be done for all women of reproductive age. Choosing the therapeutic option for the patient should be tailored according to the patient's condition, the experience of the surgeon, and the availability of facilities in the clinical setting.

Conflicts of interest

There are no conflicts of interest.

Funding source

The authors did not receive any source of fund.

Data sharing statement

Supplementary data can be shared with the corresponding author upon reasonable request.

REFERENCES

- Riaz RM, Williams TR, Craig BM, Myers DT. Cesarean scar ectopic pregnancy: imaging features, current treatment options, and clinical outcomes. *Abdom Imaging*. 2015;40(7):2589-2599. doi: 10.1007/s00261-015-0472-2.
- Barash JH, Buchanan EM, Hillson C. Diagnosis and management of ectopic pregnancy. *Am Fam Physician*. 2014;90(1):34-40.
- Refaat B, Dalton E, Ledger WL. Ectopic pregnancy secondary to in vitro fertilisation-embryo transfer: pathogenic mechanisms and management strategies. *Reprod Biol Endocrinol*. 2015;13(1):30. doi: 10.1186/s12958-015-0025-0.
- Patel MA. Scar ectopic pregnancy. *J Obstet Gynaecol India*. 2015;65(6):372–375. doi: 10.1007/s13224-015-0817-3.
- Kumari V, Kumar H, Datta MR. The importance of ectopic mindedness: scar ectopic pregnancy, a diagnostic dilemma. *Cureus*. 2021;13(2):e13089 doi: 10.7759/cureus.13089.
- Jayaram PM, Okunoye GO, Konje J. Caesarean scar ectopic pregnancy: diagnostic challenges and management options. *Obstetrician Gynaecologist*. 2017;19(1):13-20. doi: 10.1111/tog.12355.
- Sehgal N. Efficacy of color doppler ultrasonography in differentiation of ovarian masses. *J Midlife Health*. 2019;10(1):22-28. doi: 10.4103/jmh.JMH_23_18.
- Nori W, Shallal F, Roomi AB. Prediction of successful induction of labor using ultrasonic fetal parameters. *Curr Women's Health Rev*. 2022;18(1):e201221189952. doi: 10.2174/1573404817666210105151803.
- Hirschler LE, Soti V. The utility of monitoring beta-human chorionic gonadotropin levels in an ectopic pregnancy. *Cureus*. 2023;15(1):e34063. doi: 10.7759/cureus.34063.

10. Berhe ET, Kiros K, Hagos MG, Gesesew HA, Ward PR, Gebremeskel TG. Ectopic pregnancy in Tigray, Ethiopia: A cross-sectional survey of prevalence, management outcomes, and associated factors. *J Pregnancy*. 2021;2021:1-8. doi: 10.1155/2021/4443117. eCollection 2021.
11. Maheux-Lacroix S, Li F, Bujold E, Nesbitt-Hawes E, Deans R, Abbott J. Cesarean scar pregnancies: A systematic review of treatment options. *J Minim Invasive Gynecol*. 2017;24(6):915-925. doi: 10.1016/j.jmig.2017.05.019.
12. Elguero S, Patel B, Jones AV, Hurd WW, (Eds.), *Abnormal Uterine Bleeding*. In: *Clinical Reproductive Medicine and Surgery: A Practical Guide*, Springer International Publishing, 2022; pp. 171-199.
13. Cordasco KM, Yuan AH, Danz MJ, Farmer MM, Jackson L, Yee EF, et al. Guideline adherence of veterans health administration primary care for abnormal uterine bleeding. *Womens Health Issues*. 2019;29(2):144-152. doi: 10.1016/j.whi.2018.12.004.
14. Lee R, Dupuis C, Chen B, Smith A, Kim YH. Diagnosing ectopic pregnancy in the emergency setting. *Ultrasonography*. 2018;37(1):78-87. doi: 10.14366/usg.17044.
15. Tsakiridis I, Chatzikalogiannis I, Mamopoulos A, Dagklis T, Tsakmakidis G, Athanasiadis A, et al. Cesarean scar pregnancy: A case report with surgical management after initially effective conservative treatment. *Int J Surg Case Rep*. 2019;65:238-241. doi: 10.1016/j.ijscr.2019.11.002.
16. Yang H, Li S, Ma Z, Jia Y. Therapeutic effects of uterine artery embolisation (UAE) and methotrexate (MTX) conservative therapy used in treatment of cesarean scar pregnancy. *Arch Gynecol Obstet*. 2016;293(4):819-823. doi: 10.1007/s00404-015-3881-0.
17. Conti V, Luciano G, Pecoraro G, Iovieno R, Filippelli A, Guida M. Multidosing intramuscular administration of methotrexate in interstitial pregnancy with very high levels of β -hCG: A case report and review of the literature. *Front Endocrinol (Lausanne)*. 2018;9:363. doi: 10.3389/fendo.2018.00363.
18. Peng P, Gui T, Liu X, Chen W, Liu Z. Comparative efficacy and safety of local and systemic methotrexate injection in cesarean scar pregnancy. *Ther Clin Risk Manag*. 2015;137-142. doi: 10.2147/TCRM.S76050.
19. Ko JK, Li RH, Cheung VY. Cesarean scar pregnancy: a 10-year experience. *Aust N Z J Obstet Gynaecol*. 2015;55(1):64-69. doi: 10.1111/ajo.12273.
20. Michaels AY, Washburn EE, Pocius KD, Benson CB, Doubilet PM, Carusi DA. Outcome of cesarean scar pregnancies diagnosed sonographically in the first trimester. *J Ultrasound Med*. 2015;34:595-599. doi: 10.7863/ultra.34.4.595.
21. Ouyang Y, Li X, Yi Y, Gong F, Lin G, Lu G. First-trimester diagnosis and management of Cesarean scar pregnancies after in vitro fertilization-embryo transfer: a retrospective clinical analysis of 12 cases. *Reprod Biol Endocrinol*. 2015;13:126. doi: 10.1186/s12958-015-0120-2.
22. Polat I, Ekiz A, Acar DK, Kaya B, Ozkose B, Ozdemir C, et al. Suction curettage as first line treatment in cases with cesarean scar pregnancy: feasibility and effectiveness in early pregnancy. *J Matern Fetal Neonatal Med*. 2016;29(7):1066-1071. doi: 10.3109/14767058.2015.1034100.
23. Kong D, Dong X, Qi Y. Ultrasonography-guided multidrug stratification interventional therapy for cesarean scar pregnancy. *Arch Gynecol Obstet*. 2015;292(1):143-148. doi: 10.1007/s00404-014-3602-0.
24. Seow KM, Wang PH, Huang LW, Hwang JL. Transvaginal sonoguided aspiration of gestational sac concurrent with a local methotrexate injection for the treatment of unruptured cesarean scar pregnancy. *Arch Gynecol Obstet*. 2013;288(2):361-366. doi: 10.1007/s00404-013-2765-4.
25. Kutuk MS, Uysal G, Dolanbay M, Ozgun MT. Successful medical treatment of cesarean scar ectopic pregnancies with systemic multidose methotrexate: single-center experience. *J Obstet Gynaecol Res*. 2014;40(6):1700-1706. doi: 10.1111/jog.12414.
26. Wang H, Zhang J, Li YN, Wei W, Zhang DW, Lu YQ, et al. Laparoscopic management or laparoscopy combined with transvaginal management of type II cesarean scar pregnancy. *JSLs*. 2013;17(2):263-272. doi: 10.4293/108680813X13654754535197.
27. Li H, Go HY, Han JS, Wang JL, Xiong GW, Shen J, et al. Endoscopic treatment of ectopic pregnancy in a cesarean scar. *J Minim Invasive Gynecol*. 2011;18(1):31-35. doi: 10.1016/j.jmig.2010.08.002.
28. Birch Petersen K, Hoffmann E, Ribbjerg Larsen C, Svarre Nielsen H. Cesarean scar pregnancy: a systematic review of treatment studies. *Fertil Steril*. 2016;105(4):958-967. doi: 10.1016/j.fertnstert.2015.12.130.
29. Ash A, Smith A, Maxwell D. Cesarean scar pregnancy. *BJOG*. 2007;114(3):253-263. doi: 10.1111/j.1471-0528.2006.01237.x.
30. Barnhart KT, Gosman G, Ashby R, Sammel M. The medical management of ectopic pregnancy: a meta-analysis comparing "single dose" and "multidose" regimens. *Obstet Gynecol*. 2003;101(4):778-784. doi: 10.1016/s0029-7844(02)03158-7.
31. Malhotra N, Noor N, Bansal P, Sharma KA. Successful management of caesarean scar ectopic pregnancies: A report of five cases. *J Reprod Infertil*. 2021;22(3):220-224. doi: 10.18502/jri.v22i3.6723.
32. Shen F, Lv H, Wang L, Zhao R, Tong M, Lee AC, et al. A comparison of treatment options for type 1 and type 2 cesarean scar pregnancy: A retrospective case series study. *Front Med (Lausanne)*. 2021;8:671035. doi: 10.3389/fmed.2021.671035.
33. Jin X, Liu M, Zhang P, Zheng L, Qi F. Subsequent fertility after cesarean scar pregnancy: a retrospective analysis. *BMC Pregnancy Childbirth*. 2023;23(1):337. doi: 10.1186/s12884-023-05584-8.
34. Morente LS, León AIG, Reina MPE, Herrero JRA, Mesa EG, López JSJ. Cesarean scar ectopic pregnancy-case series: Treatment decision algorithm and success with medical treatment. *Medicina (Kaunas)*. 2021;57(4):362. doi: 10.3390/medicina57040362.