



Research Article

Azilsartan Attenuates Lesion Area of Thermally-Induced Burn in Rats: A Comparative Study with Silver Sulfadiazine

Hawkar Qadir Baiz¹ , Aram Ismael Ibrahim² , Zheen Aorahman Ahmed³ , Tavga Ahmed Aziz^{3*} 

¹Department of Clinical Pharmacy, College of Pharmacy, University of Sulaimani, Sulaimani, Kurdistan Region, Iraq;

²Department of Pharmaceutics, College of Pharmacy, University of Sulaimani, Sulaimani, Kurdistan Region, Iraq;

³Department of Pharmacology and Toxicology, College of Pharmacy, University of Sulaimani, Sulaimani, Kurdistan Region, Iraq

Received: 28 November 2023; Revised: 29 December 2023; Accepted: 13 January 2024

Abstract

Objective: To explore the beneficial effects of azilsartan in rat models of burn wounds. **Methods:** Forty male rats were divided into four groups: The negative control group (NC) of 4 animals used as controls. Positive control group (PC), azilsartan-treated group (AZ), and silver-sulfadiazine group (SV). Each group consisted of twelve rats with burn injuries, subdivided into three subgroups each of four (euthanized on days 7, 14, and 21 post-burn injury induction). **Results:** The levels of RBC, platelets, and HGB in the treated groups did not vary significantly. The AZ group had significantly greater WBC levels, while the AZ and SV groups had significantly higher lymphocyte levels than the PC group. After 7 days of treatment, both the PC and AZ groups showed a significant improvement in lesions and burn area, but the SV group showed no significant improvement. The improvement was considerable after 14 days of treatment in the SV-treated group and the AZ group, with no meaningful changes evident after 7 days of treatment in either of the indicated groups. When compared to the initial day of induction, no significant reduction was found in the PC group after 7 and 14 days of treatment. After 21 days of induction, the control group showed a considerable reduction in lesion and burn area. On the last day of treatment, however, the AZ and SV groups showed a more dramatic decline. **Conclusions:** Azilsartan heals the burnt area effectively, which could be related to limiting the local effects of Ag II, and deserves to be evaluated in a clinical environment.

Keywords: Azilsartan, Burn wound, Experimental animal, Silver sulfadiazine.

يخفف أزيسارتان منطقة الضرر من الحرق المستحث حراريا في الجرذان: دراسة مقارنة مع سلفاديازين الفضة

الخلاصة

الهدف: استكشاف الآثار المفيدة للأزيسارتان في نماذج الجرذان من جروح الحروق. **الطريقة:** تم تقسيم أربعين من ذكور الجرذان إلى أربع مجموعات: مجموعة التحكم السلبية المكونة من 4 تستخدم كعناصر تحكم. مجموعة التحكم الإيجابية، المجموعة المعالجة بأزيسارتان، ومجموعة سلفاديازين الفضة وتألفت كل مجموعة من اثني عشر جرذا مصابا بحروق، مقسمة إلى ثلاث مجموعات فرعية كل منها أربع (القتل الرحيم في الأيام 7 و 14 و 21 تحريض إصابة ما بعد الحرق). **النتائج:** لم تختلف مستويات كرات الدم الحمراء والصفائح الدموية و HGB في المجموعات المعالجة بشكل كبير. كان لدى مجموعة AZ مستويات WBC أكبر بكثير، في حين أن مجموعات AZ و SV لديها مستويات ليمفاوية أعلى بكثير من المجموعة الضابطة. بعد 7 أيام من العلاج، أظهرت كل من مجموعات PC و AZ تحسنا كبيرا في الأفات ومنطقة الحروق، لكن مجموعة SV لم تظهر أي تحسن كبير. كان التحسن كبيرا بعد 14 يوما من العلاج في المجموعة المعالجة SV ومجموعة AZ، مع عدم وجود تغييرات ذات مغزى واضحة بعد 7 أيام من العلاج في أي من المجموعات المشار إليها. بالمقارنة مع اليوم الأول من الحث، لم يتم العثور على انخفاض كبير في مجموعة PC بعد 7 و 14 يوما من العلاج. بعد 21 يوما من الحث، أظهرت المجموعة الضابطة انخفاضا كبيرا في منطقة الآفة والحرق. ومع ذلك، في اليوم الأخير من العلاج، أظهرت مجموعات AZ و SV انخفاضا أكثر دراماتيكية. **الاستنتاجات:** أزيسارتان يشفي المنطقة المحروقة بشكل فعال، والتي يمكن أن تكون مرتبطة بالحد من الآثار الموضعية ل Ag II، ويستحق التقييم في دراسة سريرية.

* **Corresponding author:** Tavga A. Aziz, Department of Pharmacology and Toxicology, College of Pharmacy, University of Sulaimani, Kurdistan Region, Iraq; Email: tavga.aziz@univsul.edu.iq

Article citation: Baiz HQ, Ibrahim AI, Ahmed ZA, Aziz TA. Azilsartan Attenuates Lesion Area of Thermally-Induced Burn in Rats: A Comparative Study with Silver Sulfadiazine. *Al-Rafidain J Med Sci.* 2024;6(1):63-68. doi: <https://doi.org/10.54133/ajms.v6i1.429>

© 2024 The Author(s). Published by Al-Rafidain University College. This is an open access journal issued under the CC BY-NC-SA 4.0 license (<https://creativecommons.org/licenses/by-nc-sa/4.0/>).



INTRODUCTION

The renin-angiotensin system (RAS) plays a crucial role in regulating arterial pressure, blood volume, electrolyte balance, and systemic vascular resistance. It is responsible for both acute and chronic changes in blood pressure [1]. RAS has been identified as an endocrine system that controls blood pressure and fluid-electrolyte balance via hormones and peptides. Recent research has shown that RAS is not only present in the circulatory system but also in organs where it functions locally [2]. The skin, heart, lungs, kidneys, liver, and most other organs and tissues have a tissue renin-angiotensin system (tRAS). This system works as an autocrine/paracrine system and [3] controls tissue homeostasis, which includes tissue metabolism and proliferation. [4]. Like the systemic RAS, the tRAS consists of angiotensin II (AngII) as its primary effector molecule. AngII has the ability to interact with two types of receptors, namely angiotensin receptor 1 (AT1) and angiotensin receptor 2 (AT2). The chymase and angiotensin-converting enzyme (ACE) combine to produce AngII from angiotensin I (AngI). The AT1 receptor is considered to mediate most of the known consequences of RAS activation, including fibrosis. Angiotensin-1-7 (Ang1-7) is a peptide derived from AngII that exerts its effects via the activation of the Mas receptor. It is widely believed that Ang1-7 blocks the effects of the AT1 receptor [5]. The local tRAS has been suggested as a potential mediator in the processes of wound healing and fibrosis. Several pathological processes of the skin rely on RAS components. These processes include inflammation, scar formation, fibrosis, and several skin cancers [6]. The healing of wounds is a dynamic process that may be broken down into three distinct stages: inflammation, proliferation, and remodeling [7]. In the skin, the activation of tRAS occurs in response to tissue injury, particularly in the context of inflammation. This activation process is associated with significant proinflammatory outcomes, including enhanced vascular permeability, the development of edema, and the involvement of cellular proliferation, fibrosis, and inflammation [8,9]. Therefore, agents that block this system might be effective in wound healing. Burn injuries may arise from several causes, including but not limited to heat, friction, cold, radiation, chemical exposure, or electric sources [10]. Burn injuries, even those of a relatively minor nature, may have long-lasting functional and cosmetic consequences that last for the duration of the patient's life. The issue of burns and their management has been recognized as a significant medical concern dating back to ancient times. Burn-related mortality is estimated at approximately 265,000 deaths, with 11 million burn injuries annually worldwide [10,11]. The prompt implementation of suitable therapeutic approaches immediately after the onset of burns not only has the potential to save the patient's life but also to reduce their duration of hospitalization and expedite the healing

process. Various pharmacological and nonpharmacological approaches are used in the management of burns; one of the topical and effective agents that is commonly used is silver sulfadiazine cream (SSD). Many research studies have looked into what happens to burn injuries and scars when the RAS is blocked with drugs like angiotensin-converting enzyme inhibitors (ACEIs) and angiotensin receptor blockers (ARBs). Topical application of an ACE inhibitor (captopril) reduced the level of inflammation and prevented excessive scarring in a wound scar model on rabbit ears [12]. However, Johanneke *et al.* [13] state that early captopril treatment of burn wounds did not show beneficial effects. One study suggests that the use of oral ARBs in animal models impairs fibroblast migration and delays wound healing [14]. The application of 1% valsartan gel facilitated and significantly accelerated wound closure in diabetic mice and aging pigs [15]. Maria *et al.* [16] found that losartan accelerates wound repair and normalizes wound stromal responses, having a beneficial role in the wounds of diabetic individuals. Keshvad *et al.* [17] also showed that applying losartan topically made the Vancouver Scar Scale (VSS) scores much better after three months. These scores included vascularity, pigmentation, pliability, and height. Patients taking oral ARBs and ACEIs demonstrated improved scar width in post-surgical scars [18]. To the best of our knowledge, the wound healing potential of azilsartan has not been studied yet; accordingly, this study has been designed to explore the possible beneficial effects of azilsartan in a rat model of burn wound.

METHODS

Animals

Forty male adult Wistar rats, weighing 250–350g, were obtained from the animal house of the University of Tikrit, housed in the animal house, College of Pharmacy, University of Sulaimani and kept in well-ventilated plastic cages at an ambient temperature of $25\pm 2^{\circ}\text{C}$ and humidity of $55\pm 5\%$. The room was on a 12-hour light-dark cycle. Standard rodent chow and tap water were available ad libitum. The animals were kept for one week before the experiment for acclimatization. The experimental protocols met the Guidelines for Animal Experimentation and were approved by the Research and Ethics Committee of the University of Sulaimani, College of Pharmacy (Certificate No.PH103-23 on June 12, 2023). The study was performed in accordance with the Canadian Council on Animal Care (CCAC) guidelines (1998). The animals were randomly divided into four groups, as follows: Negative control group (NC): consisted of 4 animals used as controls for biochemical tests. Positive control group (PC): twelve rats with burn injuries who received no treatment, subdivided into three subgroups each of 4

(euthanized on days 7, 14, and 21 post-burn injury induction). Azilsartan-treated group (AZ): twelve rats with burn injuries received azilsartan gel (1%) topically from the start of burn induction, subdivided into three subgroups each of 4 (euthanized on days 7, 14, and 21 post-burn injury induction). Silver-sulfadiazine group (SV): twelve rats with burn injuries received silver-sulfadiazine cream (Silvderma® 1% cream, ALDO-UNIÓN, Spain) topically from the start of burn induction, subdivided into three subgroups each of 4 (euthanized on days 7, 14, and 21 post-burn injury induction).

Induction of burn injury

To create a burn wound, the rats were anesthetized by intraperitoneal injections of ketamine (50 mg/kg) and xylazine (5 mg/kg). After shaving their backs hair with a blade and disinfection with 70% alcohol, a deep second-degree burn wound was created by a metal bar with dimensions of 2×2 cm that was heated to 105°C for 15 seconds, and an area of about 4 cm² was burned by applying the heated bar for 5 seconds without applying pressure. Thereafter, treatment was initiated with different materials on a daily basis until the end of the experiment.

Preparation of azilsartan gel

Chemicals used in the preparation: Azilsartan powder, carbopol 940, ethanol, propylene glycol, and triethanolamine. The necessary quantity of carbopol 940 powder was dissolved in distilled water to create 1% carbopol 940 hydrogel, which was then allowed to sit for a few days to allow the polymer to swell. Next, 0.5% ethanol-based solutions of azilsartan were made. Using a magnetic stirrer, the drug solution and the hydrogel that had been prepared were mixed. Triethanolamine was added in the right amounts to neutralize the pH of the hydrogel, and propylene glycol (10%) was added to make it easier for drugs to pass through and keep the gel fresh [19].

Biochemical parameters and assessment of burn area

Every seven days of the study, four animals in each group were euthanized, two milliliters of blood were drawn from each rat and added into EDTA tubes for assessment of complete blood count (CBC). The burn area was photographed for macroscopic evaluation and its size was measured using ImageJ software, (NIH, USA) at days 0, 3, 7, 14, and 21 of the study. The area of the wound was expressed as cm².

Statistical analysis

The statistical analysis was performed using GraphPad Prism 8. The values of the measured parameters were expressed as mean ± standard deviation (S.D.). For the comparisons between different groups, one-way analysis of variance (ANOVA) was followed by Tukey's test to compare each group with the positive control group. The results were considered statistically significant when the p-value was less than 0.05.

RESULTS

Table 1 shows the effect of azilsartan on the hematological markers, where no significant changes were observed in the levels of RBC, platelets, and HGB in each of the treated groups ($p>0.05$). Meanwhile, WBC levels were significantly higher in the AZ group compared to the PC group ($p<0.05$), lymphocyte levels were significantly higher in the AZ and SV groups compared to the PC group ($p<0.05$). Additionally, HCT% was significantly lower in the AZ group and was comparable to that of the NC group when compared to the PC group ($p<0.05$). A significant decrease was observed in the SV group when compared to the PC group ($p<0.05$), and this was parallel to that produced by the negative control group. Figure 1 shows the improvement of lesions and the area of burn, where a significant reduction was observed in both the PC and AZ groups after 7 days of treatment when compared to the first day of induction ($p<0.05$).

Table 1: Effect of Azilsartan on the hematological markers of thermally-induced burn in rats

Groups n=12	WBC (10 ³ /uL)	RBC (10 ⁹ /L)	Platelet (10 ³ /uL)	Lymphocyte (10 ³ /uL)	Monocyte (10 ³ /uL)	Neutrophil (10 ³ /uL)	HGB g/dl	HCT %
NC	20.11±0.4	7.58±0.01	788.5±51	14.475±0.95	1.43±0.66*	4.17±0.16*	14.6±0.28	38.1±0.98*
PC	19.5± 7	7.2±0.35	731.9± 97	13.764±4.4	2.2±2.5	3.48±3	15.3±1	42±2.9
AZ	21.4±5*	6.8±0.5	744±112	15.768±2.7*	1.97±1.8	3.6±1.3	14.3±1.2	39.1±2.7*
SV	20.5±2.8	7.4±0.34	726.9±81	15.5±2.1*	1.29±0.6*	3.67±0.78	15.6±0.6	41.5±1.9

Values are mean±SD. n: number of animals; * significantly different compared to positive control group (PC) in each group (paired t-test, $p<0.05$); NC: negative control, PC: positive control, AZ: azilsartan, and SV: silver sulfadiazine.

No significant change was noted with the SV group ($p>0.05$), (Figures 1 A–C). After 14 days of treatment, the improvement of lesions and the area of burn were significant in the SV-treated group ($p<0.05$) and the AZ group ($p<0.01$) when compared to the first day of induction, but no significant changes appeared after 7

days of treatment in each of the mentioned groups. No significant reduction was observed in the PC group after 7 and 14 days of treatment when compared to the first day of induction ($p>0.05$), (Figures 2 A–C).

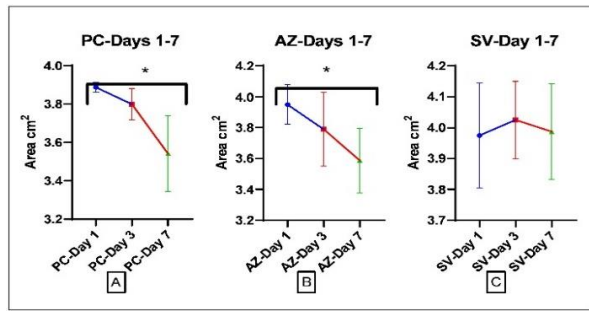


Figure 1: Burn area for days 1-7. A) Positive control group (PC), B) Azilsartan group (AZ), and C) Silver sulfadiazine group (SV); * ($p < 0.05$) significantly different compared to the first day of induction using one-way ANOVA and paired *t*-test.

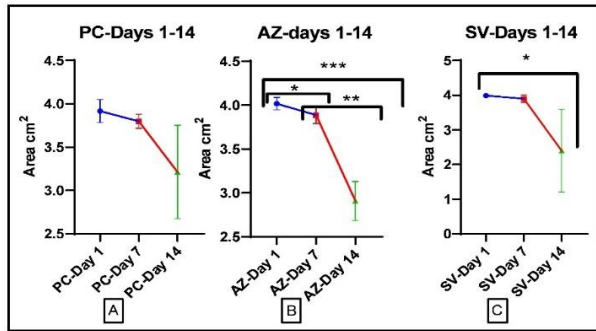


Figure 2: Burn area for days 1-14. A) Positive control group (PC), B) Azilsartan group (AZ), and C) Silver sulfadiazine group (SV); * ($p < 0.05$), ** ($p < 0.01$), and *** ($p < 0.001$) significantly different compared to day 1 and 7 using one-way ANOVA and paired *t*-test.

The current study revealed a significant reduction in the lesion and burn area in the control group after 21 days of induction ($p < 0.05$). However, a more pronounced reduction was observed in the AZ and SV groups at the last day of treatment ($p < 0.01$) and ($p < 0.001$) respectively (Figures 3 A–C).

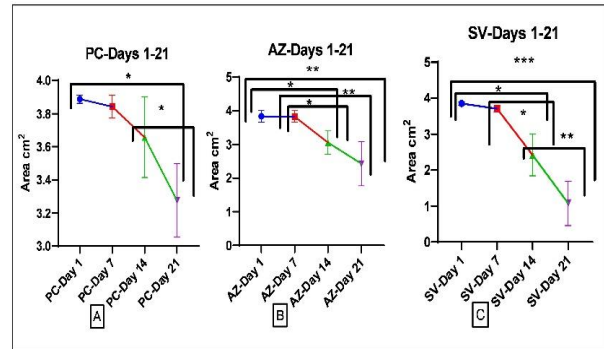


Figure 3: Burn area for days 1-21. A) Positive control group (PC), B) Azilsartan group (AZ), and C) Silver sulfadiazine group (SV); * ($p < 0.05$), and ** ($p < 0.01$) significantly different compared to days 1, 7 and 14 using one-way ANOVA and paired *t*-test.

Figure 4A shows the significant reduction in PC and AZ groups after 7 days of induction; meanwhile, Figure 4B revealed a significant reduction in burnt area in all the groups, with the maximum effect appearing on the SV group, which was statistically not significant when compared to the AZ group after 14 days of treatment, and both SV and AZ produced significant reductions when compared to the PC group ($p < 0.05$).

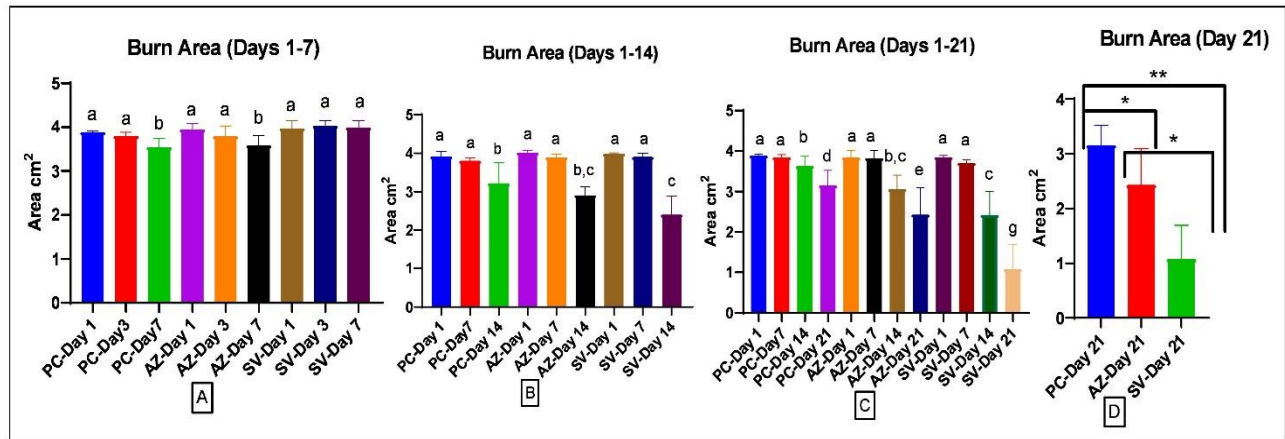


Figure 4: Burn area for all groups, A) Days 1-7, B) Days 1-14, C) Days 1-21, and D) Day 21 of each group; Values with non-identical letters (a,b,c,d,e,g) are significantly different among groups. * ($p < 0.05$), and ** ($p < 0.01$) significantly different compared to the positive control group using one-way ANOVA and unpaired *t*-test.

After 21 days of treatment, the SV group showed a maximum reduction in the burnt area compared to the PC group ($p < 0.01$) and the AZ group ($p < 0.05$). Azilsartan groups also resulted in a significant reduction when compared to the PC group ($p < 0.05$) (Figure 4C and D).

DISCUSSION

The current study aimed to investigate the healing effects of azilsartan on thermally induced burns in rats. The findings of the current study emphasized the

potential of azilsartan in facilitating the process of wound healing in burn injuries. Regarding the hematological markers, it was observed that azilsartan did not result in any significant alterations in the level of RBC and platelets. This finding suggests that azilsartan did not exert a direct influence on these particular parameters. Although peptides of the RAS are potent stimulators of progenitor cell proliferation [20], their blockade did not affect these parameters. This might be related to the fact that azilsartan is associated with increased circulating ang1-7 levels [21], which stimulates hematopoietic progenitors [20,22]. Likewise, there were no notable alterations seen in the levels of HGB within the AZ group, suggesting the lack of considerable hematological damage linked to azilsartan. In contrast, the AZ group had a notable elevation in WBC count as compared to the PC group, suggesting a potential immunomodulatory impact of azilsartan. This finding fits with the fact that the numbers of lymphocytes were much higher in the AZ and SV groups compared to the PC group. This shows that azilsartan may have an effect on how the immune system responds to burn injuries. Additionally, a significant decrease in hematocrit percentage (HCT%) was noted in the AZ group. An intact RAS is crucial for erythropoiesis in various conditions like hypertension, chronic renal insufficiency, obstructive pulmonary disease, and congestive heart failure. Accordingly, inactivation of RAS can lead to the hematocrit-lowering effects of ACEIs or ARBs, causing a dose-dependent decrease in hematocrit [23]. The burn area showed a significant decrease in size in both the AZ and PC groups after 7 days of treatment. This suggests that azilsartan may help burn wounds heal. The existing body of literature pertaining to the modification of the healing process indicates that the expression of RAS-related receptors is contingent upon the specific stage of healing, with AT1R appearing initially during the proliferation phase and, to a lesser extent, AT2R, then the process continues with downregulation of AT1R and upregulation of AT2R [7]. Previous studies have shown that RAS activation in the skin plays an important role in the wound healing process [24–26]. Furthermore, there have been suggestions indicating that the administration of systemic AT1R blockers may hinder the migration of fibroblasts and hence lead to a delay in the process of wound healing. (14) and that AT1R and AT2R may have phase-dependent effects on wound healing [27]. However, the results of the current study indicate that azilsartan initially had the potential to promote wound healing. This finding may be explained by the fact that azilsartan increases the level of ang1-7 [21], which has been found to accelerate wound healing and accelerate dermal repair [28]. Conversely, the SV group did not exhibit any significant changes, suggesting a possible limitation of silver sulfadiazine in inducing rapid burn wound closure within the initial week of treatment. After 14 and 21 days of treatment, both the AZ and SV groups demonstrated substantial improvements in burn area,

with the SV group exhibiting a more pronounced effect. Notably, azilsartan continued to exhibit a significant reduction in burn area at this stage, underscoring its promising role in facilitating the healing process. Importantly, the comparison between groups highlighted the superior efficacy of both the AZ and SV groups over the PC group, emphasizing the potential therapeutic benefits of azilsartan in the context of burn wound management. The findings of this study are consistent with previous works that pointed out the healing potential of blocking tRAS and the consequent acceleration of wound healing and wound closure [12, 15–18].

Conclusion

Azilsartan successfully heals the burn area in a manner comparable to silver sulfadiazine. This result could be attributable to azilsartan decreasing the local effects of Ag II at the wound site, highlighting the prospect of studying azilsartan in clinical settings.

ACKNOWLEDGEMENT

The authors thank the College of Pharmacy, University of Sulaimani for the support and providing facilities to conduct this project.

Conflict of interests

No conflict of interests was declared by the authors.

Funding source

The authors did not receive any source of fund.

Data sharing statement

Supplementary data can be shared with the corresponding author upon reasonable request.

REFERENCES

1. Fountain JH, Kaur J, Lappin SL. Physiology, Renin Angiotensin System. In: StatPearls. Treasure Island (FL): StatPearls Publishing; 2023. PMID: 29261862.
2. Volkan G, Abdulsamed K, Emin Ş. Role of the Renin-Angiotensin-Aldosterone System in Various Disease Processes: An Overview. In: Samy IM, (editor), Renin-Angiotensin Aldosterone System. Rijeka: IntechOpen; 2021. p. Ch. 3.
3. Nehme A, Cerutti C, Dhaouadi N, Gustin MP, Courand P-Y, Zibara K, et al. Atlas of tissue renin-angiotensin-aldosterone system in human: a transcriptomic meta-analysis. *Sci Rep*. 2015;5(1):10035. doi: 10.1038/srep10035.
4. Paul M, Poyan Mehr A, Kreutz R. Physiology of local renin-angiotensin systems. *Physiol Rev*. 2006;86(3):747-803. doi: 10.1152/physrev.00036.2005.
5. Akershoek JJ, Vlig M, Brouwer K, Talhout W, Beelen RHJ, Middelkoop E, et al. The presence of tissue renin-angiotensin system components in human burn wounds and scars. *Burns Open*. 2018;2(3):114-121. doi: 10.1016/j.burnso.2018.06.001.
6. Silva IMS, Assersen KB, Willadsen NN, Jepsen J, Artuc M, Steckelings UM. The role of the renin-angiotensin system in skin

- physiology and pathophysiology. *Exp Dermatol*. 2020;29(9):891-901. doi: 10.1111/exd.14159.
7. Hedayatyanfard K, Khalili A, Karim H, Nooraei S, Khosravi E, Haddadi NS, et al. Potential use of angiotensin receptor blockers in skin pathologies. *Iran J Basic Med Sci*. 2023;26(7):732-737. doi: 10.22038/IJBMS.2023.66563.14606.
 8. Hayden MR, Sowers KM, Pulakat L, Joginpally T, Krueger B, Whaley-Connell A, et al. Possible mechanisms of local tissue renin-angiotensin system activation in the cardiorenal metabolic syndrome and type 2 diabetes mellitus. *Cardiorenal Med*. 2011;1(3):193-210. doi: 10.1159/000329926.
 9. Santos RAS, Oudit GY, Verano-Braga T, Canta G, Steckelings UM, Bader M. The renin-angiotensin system: going beyond the classical paradigms. *Am J Physiol Heart Circ Physiol*. 2019;316(5):H958-H970. doi: 10.1152/ajpheart.00723.2018.
 10. Jeschke MG, van Baar ME, Choudhry MA, Chung KK, Gibran NS, Logsetty S. Burn injury. *Nat Rev Dis Primers*. 2020;6(1):11. doi: 10.1038/s41572-020-0145-5.
 11. Sallhi N, El Guourami O, Rouas L, Moussaid S, Moutawalli A, Benkhouili FZ, et al. Evaluation of the wound healing potential of *Cynara humilis* extracts in the treatment of skin burns. *Evid Based Complement Alternat Med*. 2023;2023:5855948. doi: 10.1155/2023/5855948.
 12. Kim DY, Han YS, Kim SR, Chun BK, Park JH. Effects of a topical angiotensin-converting enzyme inhibitor and a selective COX-2 inhibitor on the prevention of hypertrophic scarring in the skin of a rabbit ear. *Wounds*. 2012;24(12):356-364. PMID: 25876220.
 13. Akershoek JJJ, Brouwer KM, Vlig M, Boekema BKHL, Beelen RHI, Middelkoop E, et al. Early intervention by Captopril does not improve wound healing of partial thickness burn wounds in a rat model. *Burns*. 2018;44(2):429-435. doi: 10.1016/j.burns.2017.08.008.
 14. Yahata Y, Shirakata Y, Tokumaru S, Yang L, Dai X, Tohyama M, et al. A novel function of angiotensin II in skin wound healing. Induction of fibroblast and keratinocyte migration by angiotensin II via heparin-binding epidermal growth factor (EGF)-like growth factor-mediated EGF receptor transactivation. *J Biol Chem*. 2006;281(19):13209-13216. doi: 10.1074/jbc.M509771200.
 15. Abadir P, Hosseini S, Faghieh M, Ansari A, Lay F, Smith B, et al. Topical reformulation of valsartan for treatment of chronic diabetic wounds. *J Invest Dermatol*. 2018;138(2):434-443. doi: 10.1016/j.jid.2017.09.030.
 16. Kamber M, Papalazarou V, Rouni G, Papageorgopoulou E, Papalois A, Kostourou V. Angiotensin II inhibitor facilitates epidermal wound regeneration in diabetic mice. *Front Physiol*. 2015;6:170. doi: 10.3389/fphys.2015.00170.
 17. Hedayatyanfard K, Ziai SA, Habibi I, Habibi B, Moravvej H. Losartan ointment relieves hypertrophic scars and keloid: A pilot study. *Wound Repair Regen*. 2018;26(4):340-343. doi: 10.1111/wrr.12648.
 18. Hu YY, Fang QQ, Wang XF, Zhao WY, Zheng B, Zhang DD, et al. Angiotensin-converting enzyme inhibitor and angiotensin II type 1 receptor blocker: Potential agents to reduce post-surgical scar formation in humans. *Basic Clin Pharmacol Toxicol*. 2020;127(6):488-494. doi: 10.1111/bcpt.13458.
 19. Prajapati P, Zehra A, Maurya P, Singh J, Kumar A, Kushwaha S. Evaluation of azilsartan transdermal hydrogel in volumetric muscle loss injury in a rat model. *J Pharm Negative Results*. 2022;13:2517-2522. doi: 10.47750/pnr.2022.13.S05.389.
 20. Rodgers KE, Dizerega GS. Contribution of the local RAS to hematopoietic function: A novel therapeutic target. *Front Endocrinol (Lausanne)*. 2013;4:157. doi: 10.3389/fendo.2013.00157.
 21. Carroll MA, Kang Y, Chander PN, Stier CT. Azilsartan is associated with increased circulating angiotensin-(1-7) levels and reduced renovascular 20-HETE levels. *Am J Hypertens*. 2015;28(5):664-671. doi: 10.1093/ajh/hpu201.
 22. Heringer-Walther S, Eckert K, Schumacher SM, Uharek L, Wulf-Goldenberg A, Gemhardt F, et al. Angiotensin-(1-7) stimulates hematopoietic progenitor cells in vitro and in vivo. *Haematologica*. 2009;94(6):857-860. doi: 10.3324/haematol.2008.000034.
 23. Marathias KP, Agroyannis B, Mavromoustakos T, Matsoukas J, Vlahakos DV. Hematocrit-lowering effect following inactivation of renin-angiotensin system with angiotensin converting enzyme inhibitors and angiotensin receptor blockers. *Curr Top Med Chem*. 2004;4(4):483-486. doi: 10.2174/1568026043451311.
 24. Cooper ME. The role of the renin-angiotensin-aldosterone system in diabetes and its vascular complications. *Am J Hypertens*. 2004;17(11 Pt 2):16S-20S; doi: 10.1016/j.amjhyper.2004.08.004.
 25. Hao SY, Ren M, Yang C, Lin DZ, Chen LH, Zhu P, et al. Activation of skin renin-angiotensin system in diabetic rats. *Endocrine*. 2011;39(3):242-250. doi: 10.1007/s12020-010-9428-z.
 26. Yevdokimova N, Podpryatov S. The up-regulation of angiotensin II receptor type 1 and connective tissue growth factor are involved in high-glucose-induced fibronectin production by cultured human dermal fibroblasts. *J Dermatol Sci*. 2007;47(2):127-139. doi: 10.1016/j.jdermsci.2007.02.009.
 27. Faghieh M, Hosseini SM, Smith B, Ansari AM, Lay F, Ahmed AK, et al. Knockout of angiotensin AT2 receptors accelerates healing but impairs quality. *Aging (Albany NY)*. 2015;7(12):1185-1197. doi: 10.18632/aging.100868.
 28. Rodgers K, Xiong S, Felix J, Roda N, Espinoza T, Maldonado S, et al. Development of angiotensin (1-7) as an agent to accelerate dermal repair. *Wound Repair Regen*. 2001;9(3):238-247. doi: 10.1046/j.1524-475x.2001.00238.x.